



**PATIENT PRESENTING CLINICAL SIGNS**

Dixie Duffy History: Spindle tumor (hemangiopericytoma) on dorsal back. Ultrasound for possible metastatic disease.

**SPECIES** Physical Examination: N/A.

Canine Urinalysis: N/A.

**BREED** CBC: N/A.

GSD Mix Serum Biochemistry: N/A.

**SEX** Radiographic Findings: N/A.

**FS ULTRASONOGRAPHIC EXAMINATION OF THE ABDOMEN**

**AGE** *Urinary System*

11 year Full urinary bladder with a normal thickness and echogenic appearance of the wall. Normal anechoic urine with no sediment or uroliths evident.

**WEIGHT** Normal trigone area, proximal urethra, and iliac blood vessels.

45 # Normal iliac lymph nodes. Ureters not visualized.

**INTERPRETED BY** Normal renal size (left 5.8 cm, right 6.6 cm), echogenic appearance, cortico-medullary differentiation, blood flow, pelvis, and capsule. Bilateral cortical cysts (0.7 x 0.9 cm in left kidney).

Remo Lobetti, BVSc,  
MMedVet (Med), PhD, Dipl.  
ECVIM

**Reproductive System**

N/A.

**IMAGING PERFORMED BY**

Denise Bruno LVT, RDMS

**Adrenal Glands**

Normal shape, echogenic appearance, position, and size. Left 2.77 x 0.9/0.62 cm, right 2.86 x 0.94/0.69 cm).

**HOSPITAL NAME**

Kenilworth Animal  
Hospital

**Spleen**

Normal size (1.4 cm) and echogenic appearance. Smooth homogenous parenchyma, regular curvilinear capsule, and normal vasculature. No evidence of inflammatory, neoplastic, infarction, or infiltrative changes noted.

**REFERRING VET**

Dr Mansour

**Liver**

**INVOICE** Normal size, echogenic appearance, portal markings, and regular curvilinear capsule. No nodules or masses evident. Small gall bladder containing normal anechoic bile. Normal thickness and echogenic appearance of the gall bladder wall. Normal bile duct.

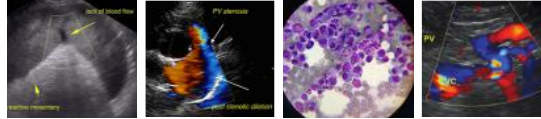
303783

**DATE**

1/18/23

**Gastrointestinal**

Normal appearance of the stomach, duodenum, small intestine, ileo-cecal junction, and colon with no loss of layering, normal wall thickness (small intestine 0.35 and 0.5 cm) and peristalsis, and no distension of the lumen.



**PATIENT** *Pancreas*

Dixie Duffy Normal size and echogenic appearance. Normal echogenic appearance of the mesentery and fat surrounding the pancreas.

**SPECIES** *Free Abdomen*

Canine No mesenteric lymphadenomegaly.  
No ascites.

**BREED**

GSD Mix **ULTRASONOGRAPHIC FINDINGS**

Primary findings:

- None.

Secondary findings:

- Renal cysts.

**SEX**

FS

**AGE**

11 year

**WEIGHT**

45 #

**INTERPRETATION OF THE FINDINGS & FURTHER RECOMMENDATIONS**

No evidence of metastatic disease on this ultrasound.

**INTERPRETED BY**

Remo Lobetti, BVSc,  
MMedVet (Med), PhD, Dipl.  
ECVIM

**IMAGING PERFORMED BY**

Denise Bruno LVT, RDMS

**HOSPITAL NAME**

Kenilworth Animal  
Hospital

**REFERRING VET**

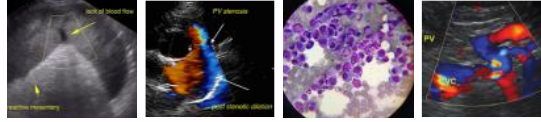
Dr Mansour

**INVOICE**

303783

**DATE**

1/18/23



**PATIENT IMAGES**

Dixie Duffy **Left kidney**

**SPECIES**

Canine

**BREED**

GSD Mix

**SEX**

FS

**AGE**

11 year

**WEIGHT**

45 #

**INTERPRETED BY**

Remo Lobetti, BVSc,  
MMedVet (Med), PhD, Dipl.  
ECVIM

**IMAGING PERFORMED BY**

Denise Bruno LVT, RDMS

**HOSPITAL NAME**

Kenilworth Animal  
Hospital

**REFERRING VET**

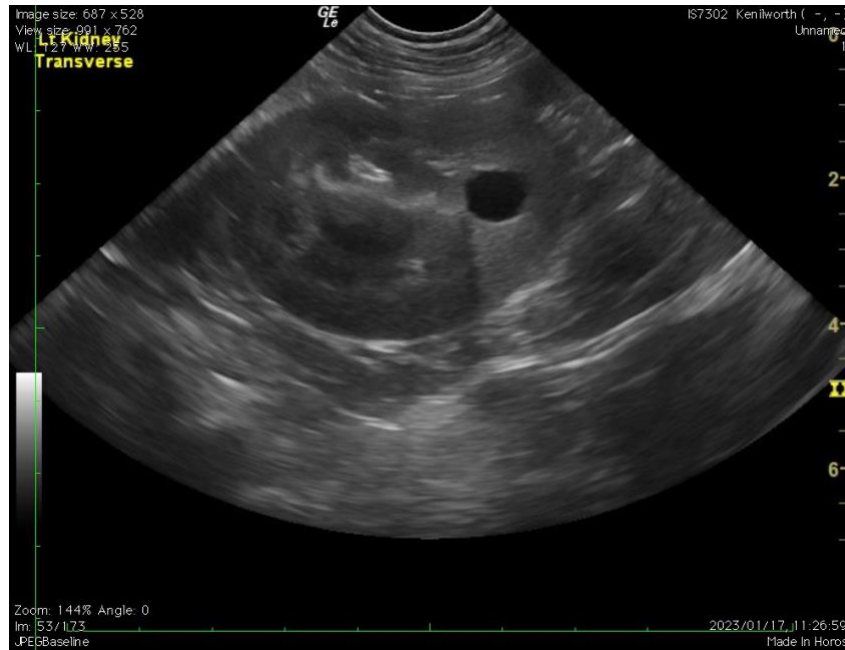
Dr Mansour

**INVOICE**

303783

**DATE**

1/18/23



The information and recommendations provided are based on the images presented by the referring veterinarian. No evaluation can be communicated regarding pathology that was not visible in the image/video clips provided.

Thank you for this referral. If the clinical or image interpretation does not parallel your findings or if I can be of any further assistance, please contact me.

**Remo Lobetti**, BVSc, MMedVet (Med), PhD, Dipl. ECVIM (Internal Medicine)  
[rlobetti@mweb.co.za](mailto:rlobetti@mweb.co.za)